



PATIENT

Olivia Pasteris

SPECIES

Feline

BREED

DSH

SEX

Female Spayed

AGE

2 years

WEIGHT

6.4lbs

INTERPRETED BY

Maggie Machen Lamy,
DVM, DACVIM
(Cardiology)

IMAGING PERFORMED BY

Dr. Belan, DVM

HOSPITAL NAME

Britannia Kingsland
Animal Hospital

REFERRING VET

Dr. Hammill

INVOICE

20529

DATE

8/12/21

PRESENTING CLINICAL SIGNS

History: Recheck echo. No murmur. No medications and nonclinical.
-Pertinent previous echo findings (8/2020 EL): Normal LA. IVSd: 0.52, LVWd: 0.41. Possible small VSD.

ECHOCARDIOGRAM FINDINGS

2D, m-mode, color flow and doppler imaging is available. The left ventricular wall is mildly increased in dimension. There is a diffusely hyperechoic endocardium consistent with fibrosis. Mild symmetric papillary muscle hypertrophy and remodeling. The right ventricle is subjectively normal in size and morphology. There is no left atrial enlargement present. No right atrial enlargement present. Normal RVOT velocity. No TR. Normal LVOT velocity. There is no obvious systolic anterior motion (SAM) of the mitral valve present. No MR. There is no pericardial effusion noted. No pleural effusion appreciated. No obvious cardiac tumors.

CARDIAC CHART

FELINE CARDIAC PARAMETERS	BODY WEIGHT (kg)	HR (BPM)	IVSd (cm) <small>(Moise, Pipers)</small>	LVIDd (cm) <small>(Moise, Pipers)</small>	LVWd (cm) <small>(Moise, Pipers)</small>	FS (%)	EF (%)
NORMAL PARAMETER	-----	150-240	0.35-0.55	<2 (mean 1.5)	3.5-0.55	35-67	80-100
PATIENT	2.9	120	0.64	1.5	0.64	55	88
FELINE CARDIAC PARAMETERS	LA/AO <small>(Boon)</small>	LA/AO HEART BASE (Swe) <small>(Abbott)</small>	LA 2D short axis Base view (cm) <small>(Abbott)</small>		LVOT VEL <small>(m/s)</small>	RVOT VEL <small>(m/s)</small>	E max <small>(m/s)</small>
NORMAL	<1.5	<1.3	<1.2		<1.6	<1.3	<0.9
PATIENT	1.2	1.3	1.1		0.83	0.83	NM

**Note: All measurements based upon multi-modal images and methods. An average value is reported.*
Adapted from June Boon, Veterinary Echocardiography, 1998
Abbott J & MacLean H JVIM 2006;20: 111-119, Moise et al. Am J Vet Res 47:1476, 1986. Pipers et al. Am J Vet Res 40:882, 1979.

INTERPRETATION OF THE FINDINGS & FURTHER RECOMMENDATIONS

Hypertrophic cardiomyopathy (HCM) is a rule out diagnosis once a patient is deemed normotensive and euthyroid. Both should be ruled out in this case as contributing factors. The degree of disease is mild, with only mild LVH and no LA dilation. This would indicate the risk for clinical issues is low at this time. Mild hypertrophy was not noted in the prior exam making this likely a new finding. No VSD appreciated. No additional issues are identified.

No medications are indicated prior to significant atrial dilation. It is important to note that no medications have been shown to definitively alter long term outcome at this stage, particularly in the absence of SAM.

Monitor at home for any respiratory issues or signs of blood clot events (neurologic change, paralysis, etc.). Anesthetic risk is considered mild, however judicious fluid administration is



PATIENT

Olivia Pasteris

SPECIES

Feline

BREED

DSH

SEX

Female Spayed

AGE

2 years

WEIGHT

6.4lbs

INTERPRETED BY

Maggie Machen Lamy,
DVM, DACVIM
(Cardiology)

IMAGING PERFORMED BY

Dr. Belan, DVM

HOSPITAL NAME

Britannia Kingsland
Animal Hospital

REFERRING VET

Dr. Hammill

INVOICE

20529

DATE

8/12/21

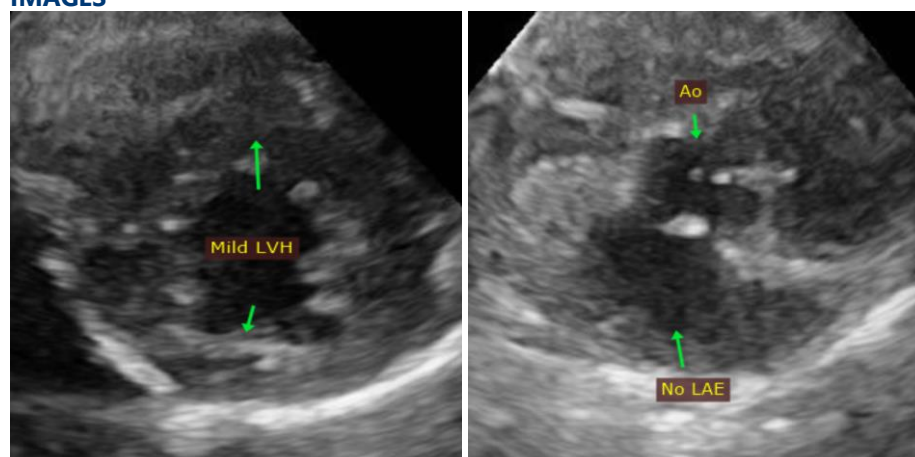
advised if needed with careful RR/RE monitoring to screen for fluid overload. Additionally, drugs that stimulate heart rate should be avoided unless clinically necessary (glycopyrrolate, atropine). Risk for complication with steroid use typically follows LA dilation, which in this case is mildly elevated. If needed, monitoring of RR/RE is advised particularly in the initiation phase.

PLAN

A screening blood pressure and T4 are recommended, then every 6 months lifelong.

A recheck echocardiogram is recommended in 6 months to assess for progression, sooner if any issues arise in the interim.

IMAGES



The information and recommendations provided are based on the images presented by the referring veterinarian. No evaluation can be communicated regarding pathology that was not visible in the image/video clips provided.

Thank you for this referral. This report was generated using transcription software, and minor dictation errors may be present. If the clinical or image interpretation does not parallel your findings or if I can be of any further assistance, please contact me.

Maggie Machen Lamy, DVM
Diplomate of the American College of Veterinary Internal Medicine (Cardiology)
info@sonopath.com